

# A New Visual Transient Elastography Technique for Grading Liver Fibrosis in Patients With Chronic Hepatitis B

Xinping Ren, MD,\* Lu Zhang, MD,\* Shujun Xia, MM,\* Zhijie Chen, MM,† Wei Zhou, MM,\* Ri Ji, MM,\* Jianqiao Zhou, MM,\* Yanyan Lin, MM,\* and Weiwei Zhan, MD\*

**Abstract:** Liver fibrosis is evaluated to assess the prognosis and guide the treatment of chronic hepatitis B (CHB). To compare the efficiency of 2 transient elastography techniques for grading liver fibrosis in CHB: visual transient elastography (ViTE) with real-time image guidance and FibroScan (FS) with no image guidance. All of the CHB patients in this study underwent both FS and ViTE examinations. The final diagnosis was based on the histological findings of a liver biopsy. According to the severity of liver fibrosis (based on the Scheuer criteria), the area under the receiver operating characteristic curve values for diagnostic efficiency were calculated for the 2 elastography techniques. This study enrolled 227 patients (79 [39.1%] women; mean age, 45.8 ± 16.8 years). The ViTE and FS liver elasticity measurements were highly correlated with liver fibrosis stage ( $r = 0.852$  and  $r = 0.813$ , respectively). The area under the receiver operating characteristic curve value was larger for ViTE compared with FS, with respect to differentiating liver fibrosis stage, but not significantly ( $P > 0.05$ ). The ViTE and FS can be used to detect and stage liver fibrosis. ViTE, easier and quicker to perform with superior interoperator reproducibility, is a stable and reliable elastography technique that benefits from real-time visual guidance.

**Key Words:** chronic hepatitis B, liver fibrosis, transient elastography, FibroScan, ViTE

(*Ultrasound Quarterly* 2020;00: 00–00)

Chronic hepatitis B (CHB) is a global health problem, with a prevalence close to 4% worldwide. Among all countries, China has the most patients infected with hepatitis B virus (HBV), which is a common cause of liver fibrosis. Without appropriate treatment, CHB can progress to hepatic fibrosis, and then to cirrhosis, hepatocellular carcinoma, or hepatic failure.<sup>1,2</sup> Thus, early diagnosis and accurate grading of hepatic fibrosis are very important to ensure timely treatment; early fibrosis may be reversible, whereas the chances of cirrhosis being

reversed are very low.<sup>3–5</sup> Accurate assessment of hepatic fibrosis can improve the treatment outcome and prognosis.<sup>6</sup>

Hepatic biopsy is the criterion standard for assessing the severity of liver fibrosis and cirrhosis.<sup>7</sup> However, it is an invasive procedure with potential complications including pain, bleeding, infection, organ perforation, and arteriovenous fistula formation. Recently, ultrasound elastography, in which the propagation velocity of shear waves or Young modulus is used to estimate liver stiffness, has been used to assess the severity of liver fibrosis.<sup>8–10</sup> Most methods for assessing the severity of liver fibrosis and cirrhosis are relatively new and require more study before they can be applied clinically.<sup>10,11</sup> The elastography technique most widely accepted internationally is transient elastography, which can be performed using the FibroScan instrument (FS; Echosens, Paris, France). It is an A mode shear wave vibroacoustic technique commonly used in clinics and hospitals and recommended by most international and Chinese guidelines related to hepatic disease and ultrasound. Nevertheless, FS has limitations when applied to patients with emphysema, obesity, or severe cirrhosis, because it provides no visual image guidance. Large vessels or lumps can prevent imaging of the appropriate liver lobes during elastography. However, a new type of transient elastography, visual transient elastography (ViTE), allows the examiner to select the sampling area under real-time image guidance, free of interference from large vessels and lumps, such that the elastography examination can be performed more stably and reliably. Most studies using FS focused on patients with advanced liver fibrosis or cirrhosis. However, the detection of mild and moderate hepatic fibrosis is more important, because early diagnosis and treatment might allow the progression of the disease to be reversed.<sup>3–5</sup>

No study has compared ViTE and FS. Therefore, in this study, we used both transient elastography techniques in patients with CHB for grading hepatic fibrosis to compare their diagnostic value for hepatic fibrosis.

## MATERIALS AND METHODS

### Study Design and Participants

The study prospectively enrolled 278 consecutive patients who were scheduled for liver biopsy in our department from November 2018 to October 2019. The exclusion criteria were as follows: (1) other liver diseases, including drug-induced liver injury, autoimmune hepatitis, and alcoholic hepatitis; (2) infection with hepatitis A or C virus, Epstein-Barr virus, human herpesvirus, and so on; (3) serum alanine aminotransferase (ALT)

Received for publication November 14, 2019; accepted February 19, 2020.

\*Ultrasound Department, Ruijin Hospital, Shanghai Jiaotong University School of Medicine, Shanghai; and †Shenzhen Mindray Biomedical Electronic Co., Ltd., Shenzhen, China.

L.Z. contributed equally to this study.

The authors declare no conflict of interest.

Address correspondence to: Xinping Ren, MD, Ultrasound Department, Ruijin Hospital, Shanghai Jiaotong University School of Medicine, No. 197, Ruijin 2 Rd, 200025, Shanghai, China (e-mail: peaceheart80@163.com); Weiwei Zhan, MD, Ultrasound Department, Ruijin Hospital, Shanghai Jiaotong University School of Medicine, No. 197, Ruijin 2 Rd, 200025, Shanghai, China (e-mail: shanghai@126.com).

Copyright © 2020 Wolters Kluwer Health, Inc. All rights reserved.

DOI: 10.1097/RUQ.0000000000000509

or aspartate aminotransferase (AST) levels 5 times higher than the reference range; (4) moderate to severe fatty liver; (5) alcohol abuse, diabetes, or obesity; (6) heart, brain, or renal disorders; and (7) gestation and lactation. Ultimately, 227 patients with CHB were included in our analysis. This study was approved by the institutional review board of our hospital, and informed consent was obtained from all patients.

## Study Protocol

### Study Instruments and Examiners

Visual transient elastography was performed using the Hepatus Resona 6S (Mindray, Shenzhen, China) equipped with a phased array probe (LFP5-1U). FibroScan was performed using the FibroScan 502 Touch device with an M transducer (Echosens); Young modulus (in kPa) was calculated separately. The FS examinations were conducted by a sonographer with more than 5 years of experience. The ViTE examinations were conducted by a sonographer with 15 years of abdominal ultrasound experience who had performed 300 ViTE examinations. Both sonographers were blinded to the liver biopsy results.

### Patient Position and Preparation for Examination

Based on the recommendations of the European Federation of Societies for Ultrasound in Medicine and Biology,<sup>12</sup> all participants were required to fast for 2 hours before the examination. Patients were examined in the dorsal decubitus position, with the right arm elevated above the head for optimal intercostal access. The left arm hung down naturally.

### Ultrasound Elastography Examination

The FS examination was performed first, followed by ViTE in a different examination room. The ViTE and FS probes were inserted parallel to the intercostal space. For ViTE, B-mode sonography was used to avoid the biliary tract, large blood vessels, and lumps. The intercostal space was appropriate to allow acquisition of the best possible images of segments 5 and 6 of the right hepatic lobe. A region of interest (ROI) was placed beneath the Glisson capsule, free of bile ducts and vessels to avoid reverberation artifacts and any effect of subcapsular stiffness (Fig. 1). Then, markers were placed on the body surface to guide puncture during the liver biopsy. The patients were asked to breathe normally, or to hold their breath for 5 to 6 s to avoid any influence of respiratory movement.

First, FS examinations were performed with the patients in the same position as described above; Young modulus of elasticity was calculated after each measurement, ten measurements were performed with interquartile range (IQR)/median (med.) less than 30%. The ViTE examinations were performed under the same conditions; 10 measurements were again obtained with IQR/med. less than 30%.

### Randomized Controlled Study

Two operators randomly evaluated 45 patients each with ViTE: a senior doctor (operator 1; 15 years of experience in abdominal ultrasound, including at least 300 performed using the Hepatus platform) and a junior doctor (operator 2; 2 years of experience in abdominal ultrasound, including 25 performed using the Hepatus platform). Interoperator variability was assessed and,

for operator 1, intraoperator variability was evaluated based on the differences between 2 measurements obtained per patient.

### Ultrasound-guided Percutaneous Liver Biopsy

After the elastography examinations, liver biopsies were performed under local anesthesia (1% lidocaine) using 16G (gauge) biopsy needle (Magnum biopsy gun; CR Bard, Inc., Covington, GA) with the patients maintained in the same position. A satisfactory biopsy was defined as a tissue longer than 1.5 cm in length containing greater than 10 hepatic structures in the portal area. The liver samples were immersed in 10% neutral formalin and embedded in paraffin, followed by hematoxylin & eosin and Masson staining. The histopathological analysis was conducted by an experienced pathologist, and the final diagnosis was confirmed by another experienced pathologist. The Scheuer scoring system was used in the pathological analysis of liver fibrosis and necroinflammatory activity.<sup>13</sup> The Scheuer inflammation grades are as follows: G0, none; G1, mild; G2, moderate; G3, moderate-to-severe; and G4, severe. The fibrosis grades are as follows: S0, no fibrosis; S1, enlarged fibrotic portal tracts; S2, portal fibrosis with rare septa; S3, fibrosis with architectural distortion, but no obvious cirrhosis; and S4, numerous fibrous septal with pseudolobule formation. Two senior pathologists who were blinded to the elastography results analyzed the biopsy specimens and produced histopathological reports.

### Statistical Analysis

All analyses were performed using SPSS software (ver. 20.0; SPSS Inc., Chicago, IL). Descriptive data are presented as mean  $\pm$  SD. Categorical data are given as proportions. Correlation analysis between liver elasticity measurements for the elastography modalities and liver fibrosis stage was performed using the Spearman correlation test. Reproducibility was investigated based on the intraclass correlation coefficient (ICC) and 95% confidence intervals (CIs) (ICC > 0.75 indicates excellent reliability). Diagnostic efficiency was compared between ViTE and FS based on the area under the receiver operating characteristic curve (AUC). Sensitivity and specificity values were calculated for both diagnostic modalities. The DeLong test was used to compare the AUC values. *P* less than 0.05 was considered statistically significant.

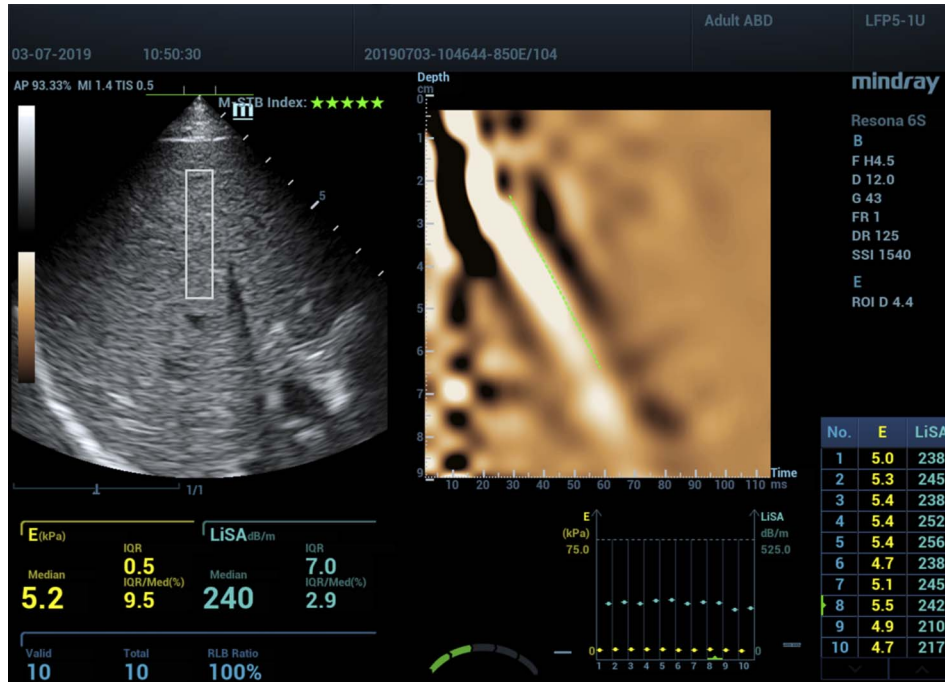
## RESULTS

### Patient Characteristics

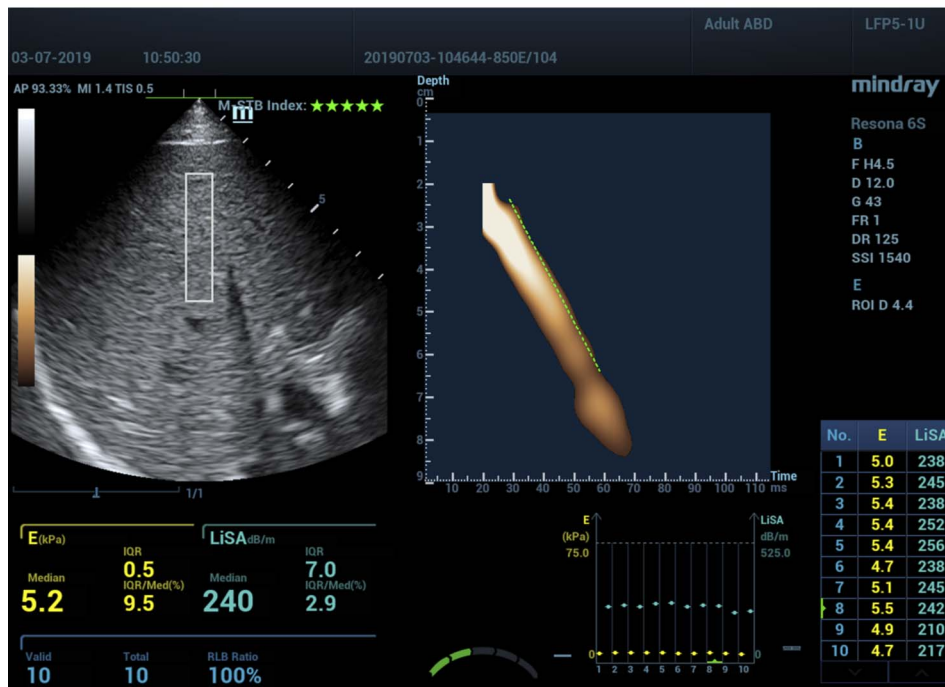
In total, 227 patients were enrolled in this study (104 women, 123 men; mean age, 45.8  $\pm$  16.8 years). There were no significant differences in sex or age between the 2 groups (*P* > 0.05). Laboratory tests showed that the serum ALT, AST,  $\gamma$ -glutamyltransferase, alkaline phosphatase, total bilirubin, and albumin were similar in both groups (*P* > 0.05) (Table 1).

### ViTE and FS Measurements by Liver Fibrosis Stage

The liver stiffness measurement success rate for ViTE was 100% (227/227); for FS, it was 98.23% (223/227). Regarding interoperator variability, ViTE had an ICC of 0.89 (95% CI, 0.84–0.95) for liver fibrosis, and the ICC for intraobserver agreement was 0.91 (95% CI, 0.83–0.96). Thus, in both cases,



A



B

**FIGURE 1.** A, The data acquisition process using ViTE. The left-hand picture is a 2-dimensional gray scale image used for guiding LFP5-1U probe placement. The final liver fibrosis measurement result obtained using ViTE (median of 10 measurements [E (kPa)<sub>median</sub>], IQR/med. <30%) is shown under the image. The right-hand picture shows the sound propagation path of ViTE; the straightness of the dotted lines indicating the main propagation path show that the measurement quality was good. B, The right-hand picture shows the propagation path for the main sound beam for ViTE, with all other sound beams removed; the straightness of the line indicates that the measurement quality was good.

agreement was very good. There were no significant differences between 2 measurements obtained per patient ( $P > 0.05$ ). The stiffness (kPa) of the liver was higher with higher fibrosis stage,

according to both ViTE and FS. The highest ViTE and FS liver elasticity values were found in S4 stage. There was a strong correlation between the ViTE/FS liver elasticity measurements and

**TABLE 1.** Characteristics of Patients

	Group 1 (ScheuerG/S ≤ 2) (n = 175)	Group 2 (Scheuer G/S ≥ 2) (n = 52)	P
Demographics			
Age: M ± SD, y	40.9 ± 13.6	44.7 ± 12.8	0.065
Sex			
Female, n (%)	26(14.9%)	12(23.1%)	0.052
Laboratory tests (M ± SD)			
ALT (IU/L)	40.46 ± 11.21	53.18 ± 22.95	0.142
AST (IU/L)	43.78 ± 22.15	46.78 ± 32.11	0.098
γ-Glutamyltransferase (IU/L)	33.12 ± 12.11	40.71 ± 22.15	0.076
Alkaline phosphatase (IU/L)	60.16 ± 32.15	75.71 ± 30.12	0.057
Total bilirubin (mol/L)	53.71 ± 32.18	63.78 ± 22.10	0.094
Albumin (g/L)	45.18 ± 12.15	43.72 ± 18.19	0.120

M ± SD, mean ± standard deviation.

fibrosis stage ( $r = 0.812/r = 0.803$ , respectively). Table 2 showed the data for the 2 elastography techniques according to liver fibrosis stage.

### Performance of ViTE and FS in Terms of Identifying Liver Fibrosis Stage

The diagnostic sensitivity and specificity of ViTE and FS, respectively, for identifying different liver fibrosis stages were as follows: stage  $\geq 2$ , 88.35% and 64.71% versus 82.72% and 58.62%; stage  $\geq 3$ , 94.71% and 90.30% versus 89.33% and 86.96%; and stage  $\geq 4$ , 97.23% and 97.23% versus 96.02% and 95.21%. The diagnostic efficiency AUC values for ViTE and FS were calculated. The AUC of ViTE was larger than that of FS for identifying stage  $\geq 2$  (0.819 vs. 0.783), stage  $\geq 3$  (0.927 vs. 0.902), and stage  $\geq 4$  (0.938 vs. 0.925) liver fibrosis (Table 3).

## DISCUSSION

Hepatitis B virus infection is characterized by the aggregation of inflammatory cells in liver tissues, in addition to hepatic cell injury and collagen deposition in the extracellular matrix, due to the induction of host immune responses and reactions. HBV infection progresses to liver cirrhosis and hepatic carcinoma through a series of morphological changes. Most patients with CHB are diagnosed with severe liver fibrosis or advanced cirrhosis, as they are often asymptomatic in early disease stages. Typically, CHB patients who start treatment at an advanced stage have a poorer prognosis compared with those starting during earlier stages. Early diagnosis and intervention are of great importance for CHB patients and decrease the possibility of unfavorable clinical outcomes.<sup>1-7</sup> Currently, liver fibrosis is evaluated according to the clinical symptoms, the results of serological examinations and imaging studies, and tissue biopsies. Although serum biomarkers reflect liver function and systematic changes therein, they are easily influenced by

external factors and have low diagnostic specificity, especially in CHB patients. Liver biopsy for pathological diagnosis is invasive and expensive and has low reproducibility.<sup>8</sup> Standard imaging modalities, including conventional ultrasound, computed tomography, and magnetic resonance imaging, are not efficient in identifying early liver fibrosis. The advent of elastography has increased the diagnostic accuracy for liver fibrosis. Ultrasound elastography is cheaper and more convenient and shows higher reproducibility than magnetic resonance elastography.<sup>6,9</sup>

Ultrasound elastography can provide quantitative information on the severity of liver fibrosis, although the accuracy of the results remains controversial.<sup>12,14-18</sup> In the current study, transient elastography was conducted using FS, which is widely used to diagnose liver fibrosis and cirrhosis. So, we regarded FS as a comparative method in our study. Obesity, and the presence of diseases, such as severe cirrhosis and emphysema, may affect the results of FS examinations conducted without visual image guidance and can also lengthen the procedure time.<sup>14</sup> A new transient elastography technique, ViTE, was applied here in using the Hepatus Resona 6S ultrasound system and compared with FS for the first time. In ViTE, multiple measurements are obtained in real time under sonographic guidance, which may improve the accuracy of the tissue elasticity analysis. We examined segments 5 and 6 of the right hepatic lobe, because the low-frequency sound beam was vertical to the intercostal space in this area, and large blood vessels and the bile duct could easily be avoided; also, the measurement was less affected by breathing and biopsy was more straightforward. The final result was given by the median of 10 measurements. The liver stiffness measurement success rate of FS (98.23%) was lower than that of ViTE (100%), because FS was more affected by obesity or a small liver due to severe cirrhosis. The interoperator variability was superior for ViTE than FS; the results were more reproducible and image guidance toward the correct liver lobes

**TABLE 2.** Comparisons of Patients With Different Stages of Liver and Fibrosis by Two Elastography Techniques (kPa)

	Scheuer S ≥ 2 (n = 104)	Scheuer S ≥ 3 (n = 59)	Scheuer S ≥ 4 (n = 23)
FS	5.7 ± 2.8	10.2 ± 2.8	11.58 ± 3.65
ViTE	6.8 ± 1.4	9.3 ± 2.9	10.98 ± 3.23
P	0.098	0.189	0.102

**TABLE 3.** Diagnostic Performances of ViTE and FS

	Scheuer S ≥ 2 (n = 104)	Scheuer S ≥ 3 (n = 59)	Scheuer S ≥ 4 (n = 23)
FS			
ROC-AUC	0.783	0.902	0.925
Sensitivity, %	82.72%	89.33%	96.02%
Specificity, %	58.62%	86.96%	95.21%
Cutoff, kPa	5.4	8.8	11.8
ViTE			
ROC-AUC	0.819	0.927	0.938
Sensitivity, %	88.35%	94.71%	97.23%
Specificity, %	64.71%	90.30%	95.05%
Cutoff, kPa	6.8	8.3	11.2

enhanced the accuracy. The intraobserver reproducibility of ViTE was also excellent, where the assessments were facilitated by the high image resolution. Compared with FS, ViTE is easier and quicker to perform (5–6 s per measurement) and can be used in patients with severe cirrhosis and emphysema who cannot undergo FS examinations. In this study, the liver elasticity measurements were reproducible, operator-independent, and correlated well with the fibrosis grade.

Previous studies evaluating the diagnostic performance of elastography showed that the sensitivity and specificity for both ranged from 60% to 90%; some studies reported higher sensitivity than specificity, whereas others reported the opposite.<sup>13–20</sup> In our study, the sensitivity and specificity values were similar to those of these previous reports. The differences in results among previous studies might have been due to differences in the sonogram equipment and elastography techniques used and to differences in patient characteristics.

A previous study reported that FS was more accurate for diagnosing advanced liver fibrosis in advanced disease stages (3 and 4). A higher Young modulus value corresponds to a higher liver fibrosis stage.<sup>14–17</sup> In the present study, the ViTE and FS liver elasticity measurements were highly correlated with fibrosis stage, and the Young modulus was also higher in more advanced disease stages, as per the studies mentioned above. FibroScan measurements are more likely to be influenced by emphysema and severe cirrhosis than those of ViTE, with the latter modality, thus being better able to identify liver lobes free from vessels and lumps, thus facilitating the examination. FibroScan is an A mode shear wave vibroacoustic technique based on a single-channel system that uses several ultrasonic signals. Meanwhile, ViTE based on the Hepatus platform calculates the average hardness of liver tissues within an ROI; the high resolution of the multi-element probe can show the liver tissues in more detail. The liver tissue area evaluated by ViTE is much larger than that assessed by FS, and the echo signal detected by ViTE is more representative of the actual status of the liver tissues. Our results also showed that ViTE had greater accuracy than FS for diagnosing stage 2 to 4 liver fibrosis based on quantitative measurement of tissue elasticity. ViTE can be used to diagnose early liver fibrosis and cirrhosis in clinical screening examinations and for monitoring the efficacy of treatment.

The limitations of our study included the small sample size and single-center design. Also, the area assessed by liver biopsy (as the reference diagnostic modality) was smaller than

that measured by elastography and may not well represent the disease status of the entire liver; active inflammation of the liver parenchyma might also reduce ultrasound detection accuracy. Finally, patient height and weight, and the thickness of the subcutaneous fat layer, were not considered in this study. Whether these factors influence the measurements needs to be further explored in studies including larger sample and focusing on different stages of liver fibrosis.

### CONCLUSIONS

The ViTE and FS can be used for detecting and staging liver fibrosis. The real-time image guidance of ViTE confers more stability and reliability and also saves time. Thus, ViTE has potential in the clinical setting for noninvasive evaluation of liver fibrosis.

### REFERENCES

- Schweitzer A, Horn J, Mikolajczyk RT, et al. Estimations of worldwide prevalence of chronic hepatitis B virus infection: a systematic review of data published between 1965 and 2013. *Lancet*. 2015;386:1546–1555.
- Wright TL. Introduction to chronic hepatitis B infection. *Am J Gastroenterol*. 2006;(101 Suppl 1):S1–S6.
- Friedman SL, Bansal MB. Reversal of hepatic fibrosis fact or fantasy? *Hepatology*. 2006;43:S82–S88.
- Pinzani M, Vizzutti F. Fibrosis and cirrhosis reversibility: clinical features and implications. *Clin Liver Dis*. 2008;12:901–913.
- Calvaruso V, Craxi A. Regression of fibrosis after HBV antiviral therapy. Is cirrhosis reversible? *Liver Int*. 2014;(34 Suppl 1):85–90.
- Sarin SK, Kumar M, Lau GK, et al. Asian-Pacific clinical practice guidelines on the management of hepatitis B: a 2015 update. *Hepatol Int*. 2016;10:1–98.
- Kose S, Ersan G, Tatar B, et al. Evaluation of percutaneous liver biopsy complications in patients with chronic viral hepatitis. *Eur J Med*. 2015;47:161–164.
- Cosgrove D, Piscaglia F, Bamber J, et al. EFSUMB guidelines and recommendations on the clinical use of ultrasound elastography. Part 2: clinical applications. *Ultraschall Med*. 2013;34:238–253.
- Xiao G, Zhu S, Xiao X, et al. Comparison of laboratory tests, ultrasound, or magnetic resonance elastography to detect fibrosis in patients with nonalcoholic fatty liver disease: a meta-analysis. *Hepatology*. 2017;66:1486–1501.
- Sigrist RMS, Liau J, Kaffas AE, et al. Ultrasound elastography: review of techniques and clinical applications. *Theranostics*. 2017;7:1303–1329.
- Barr RG, Ferraioli G, Palmeri ML, et al. Elastography assessment of liver fibrosis: society of radiologists in ultrasound consensus conference statement. *Ultrasound Q*. 2016;32:94–107.
- Dietrich CF, Bamber J, Berzigotti A, et al. EFSUMB Guidelines and Recommendations on the Clinical Use of Liver Ultrasound Elastography, Update 2017 (Long Version). *Ultraschall Med*. 2017;38(4):e16–e47.
- Scheuer PJ. Classification of chronic viral hepatitis: a need for reassessment. *J Hepatol*. 1991;13:372–374.

14. Sandrin L, Fourquet B, Hasquenoph JM, et al. Transient elastography: a new noninvasive method for assessment of hepatic fibrosis. *Ultrasound Med Biol*. 2003;29:1705–1713.
15. Han KH, Yoon KT. New diagnostic method for liver fibrosis and cirrhosis. *Intervirology*. 2008;(51 Suppl 1):11–16.
16. Webb M, Shibolet O, Halpern Z, et al. Assessment of liver and spleen stiffness in patients with myelofibrosis using fibroscan and shear wave elastography. *Ultrasound Q*. 2015;31(3):166–169.
17. Ren X, Xia S, Ni Z, et al. Analysis of three ultrasound elastography techniques for grading liver fibrosis in patients with chronic hepatitis B. *Radiol Med*. 2018;123(10):735–741.
18. Xia S, Ren X, Ni Z, et al. A noninvasive method-shear-wave elastography compared with transient elastography in evaluation of liver fibrosis in patients with chronic hepatitis B. *Ultrasound Q*. 2019;35:147–152.
19. Bhat M, Tazari M, Sebastiani G. Performance of transient elastography and serum fibrosis biomarkers for non-invasive evaluation of recurrent fibrosis after liver transplantation: a meta-analysis. *PLoS One*. 2017;12(9):e0185192.
20. Geng XX, Huang RG, Lin JM, et al. Transient elastography in clinical detection of liver cirrhosis: a systematic review and meta-analysis. *Saudi J Gastroenterol*. 2016;22:294–303.